

**Case Report**

Entrapment of central venous catheter by a suture to the left atrial wall following double valve replacement

Bidhan Gyawali*, Ashish Govinda Amatya*, Battu Kumar Shrestha*, Jeju Nath Pokharel*, Nabin Chandra Gautam**

*Department of Anesthesia, Shahid Gangalal National Heart Centre, Bansbari, Kathmandu, Nepal.

** Department of Cardiovascular Surgery, Shahid Gangalal National Heart Centre, Bansbari, Kathmandu, Nepal

ARTICLE INFO**Article history**

Received 27.07.2014

Accepted 25.08.2014

Published 08.09.2014

© Authors retain copyright and grant the journal right of first publication with the work simultaneously licensed under a Creative Commons Attribution License that allows others to share the work with an acknowledgment of the work's authorship and initial publication in this journal.

ABSTRACT

A 19-year-old female with severe mitral stenosis, moderate mitral regurgitation and severe aortic regurgitation was scheduled for double valve replacement. The central venous catheter inserted after induction of anesthesia could not be pulled out on an attempt to remove it on third postoperative day, and appeared to be stuck. Fluoroscopy confirmed the fixation of catheter at left atrial wall of the heart. This necessitated reopening the chest, cutting the suture and removing the catheter. We believe that our case is one of the few reports of central venous catheter sutured surgically to the atrial wall requiring re-exploration for removal. This kind of entrapment of central venous catheter by a suture is a possible complication in open heart surgeries. Cardiovascular anesthesiologists and surgeons should take measures to prevent such complication. Any attempt to pull it out could be fatal. Cautious handling is advocated whenever an entrapped central venous catheter is found. Checking the catheter for possible entrapment by gently pulling it a few centimeters at the time of atrial wall closure and using a shorter length catheter may be the strategies to prevent such complication.

Keywords: Central venous catheterization, Complications, Heart Valve Prosthesis Implantation

How to cite this article: Gyawali B, Amatya AG, Shrestha BK, Pokharel JN, Gautam NC. Entrapment of central venous catheter by a suture to the left atrial wall following double valve replacement. JSAN 2014;1:80-82.

Introduction

Central venous catheter (CVC) placement is a routine hospital procedure frequently done in patients undergoing open heart surgery. Various complications can occur from central venous catheterization which can range from discomfort, bleeding, pneumothorax during insertion to infection, thrombosis, blockade and kinking. These

complications are commonly reported and well described in the literature. But a complication like entrapment of CVC due to suturing of the catheter into the atrial wall following an open heart surgery have been rarely reported or discussed in the literature. We report a case of CVC placed into the right subclavian vein, (supraclavicular

Correspondence: Bidhan Gyawali

Department of Anaesthesia

Shahid Gangalal National Heart Centre, Bansbari, Kathmandu, Nepal

Telephone: +977 9843125978

Email: abgyawali@yahoo.com

approach) sutured to the left atrial wall. This necessitated re-opening of the chest for removal of the CVC.

Case report

A 19 year female with severe mitral stenosis, moderate mitral regurgitation and severe aortic regurgitation was scheduled to undergo a double valve replacement under general anesthesia. Her functional status was NYHA class II. Seldinger technique was used for central venous catheterization (Biosensors, 8.5Fr, 13cm, 4 lumen) in right sub-clavian vein via supra-clavicular approach. Its proper placement in the junction of SVC (superior vena cava) and right atrium were confirmed by the ECG waveforms in the monitor and transesophageal echocardiography (TEE). Its patency was checked by free aspiration of blood from all four lumen. Her central venous pressure recording ranged from 8 to 12mmHg. Entire surgical procedure was uneventful. She was then transferred to the surgical intensive care unit (SICU). Antero-posterior view of chest X-ray showed normal positioning of the catheter. On the third postoperative day attempts for removal of the catheter was not successful. Each attempt was met with resistance. Repeat chest X-ray showed a normal straight path of the catheter upto the superior vena cava-right atrial (SVC-RA) junction followed by a tilt [Fig.1]. Patient was then taken to cath lab for fluoroscopy and gentle rotation with outward traction of CVC confirmed the entrapment at SVC-RA junction. Then a guide wire was passed through the catheter with minimal resistance but the catheter could not be removed. This led to a high suspicion of the catheter being sutured to the heart.

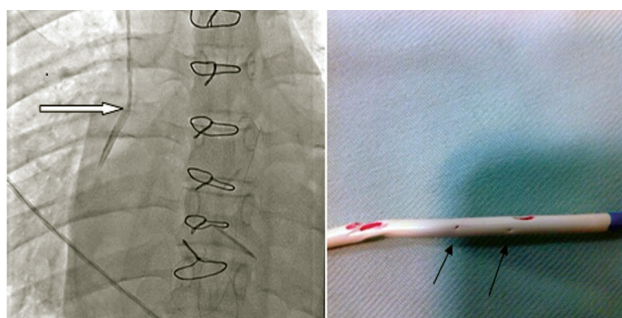


Fig1: Fluoroscopy showing tilt of the catheter at SVC-RA junction.

Fig2: CVP catheter after removal. Suture marks are clearly visible

Surgical exploration under general anesthesia was planned. TEE showed the catheter in right atrium. Preparations to go on to cardiopulmonary bypass were made. The chest was re-opened and pericardial stay suture were taken for good exposure. While traction was applied to the catheter externally, tissue-traction at the left atrial suture line was clearly visualized indicating traction over the second layer of left atrial closure suture. It was clear that the catheter entrapment was nearly 1.5 cm below the RA to SVC

junction. Double arm 4-0 prolene suture was taken nearly 1 cm above and below the site of entrapment ensuring that this suture again does not catch the catheter. The second layer prolene suture were cut releasing the catheter from its entrapment and successful removal was made [Fig.2]. Though first layer left atrial closure suture were intact and there was no bleeding from left atriotomy site, reinforced sutures were taken above and below the site. The re-exploration and removal of the catheter was uneventful. Patient was taken back to ICU and transferred out from the ICU on the next day.

Discussion

Accidental suturing of catheters to the heart is an unusual but a very likely complication in open heart surgeries. Positioning the tip of the CVC in the atrium, especially near the wall of suture line, can increase the likelihood of suturing the CVC to the heart. There have been few reports of suturing of CVC or pulmonary artery catheters (PAC) to heart and vessels by cardiac sutures.^{ii,iii,iv}, Kaplan et al surveyed 10 cases of PAC entrapment complications, all of which involved valvular replacement surgeries.^v Huang et al similarly reported entrapment of a Swan-Ganz catheter in the purse-string suture in a patient undergoing aortic valve replacement.^{vi} All of these cases have a similarity of being valvular surgeries, including this case.

The insertion of CVC is usually preferred through IJV but in the postoperative period, patients complained of catheter traction pain and discomfort over the neck. To avoid this discomfort we frequently use subclavian vein for CVC cannulation through supraclavicular approach. We found it is comparatively comfortable and less painful as compared to IJV cannulation and also less influenced by sternal retractor than the infraclavicular approach.

We use shorter length of CVC to minimize the catheter position in RA, however there is variation in the size of the patients. We observed the size of the LA frequently "giant" in mitral valvular disease especially in MS which may contribute to the extension of LA wall upto the level of SVC – RA junction or beyond. The other possibility of suturing of catheter in LA suture may be the migration of the catheter in the posterior wall of the RA cavity.

Diagnostic methods such as chest radiographs and transesophageal echocardiography can be used to confirm the position of catheter tip. Transesophageal echocardiography provides a more sensitive assessment than chest radiography in monitoring the position of the catheter. Although in our case report, we could not provide the TEE images done which has now become a must in this era of Echo based cardiac anesthetic practice. Fluoroscopy is very helpful in confirming the entrapment. As we see in our case, acute angulation of the catheter on chest radiograph is an important diagnostic sign of suture entrapment.ⁱⁱ Once the entrapment is confirmed or even suspected, cautious handling of the CVC is advocated. Gentle traction and passing of guide wire can be tested

to move the catheter. In cases of suturing to the heart, excessive traction can lead to breakage of the catheter as well as opening or rupture of the suture line. Atrial wall lacerations can also occur. Hence, surgical management of such suturing is preferable than any other non-surgical procedures. A patient undergoing an open heart surgery may have poor heart function and have low tolerance to any additional insults hence, conscious effort to prevent this complication is necessary. Care should be taken while closing the atrial cannulation site. One preventive measure can be the pulling of CVC for few centimeters by anesthesiologist during tying of purse-string sutures at the venous cannulation site. If any resistance is felt, the suture can be gently loosened and the catheter pulled out of the suture line into the cephalic portion of the superior vena cava. If the complication is realized postoperatively, it must be managed surgically.^{ii,iv,v,vi} Other measure could be using a shorter length catheter which is being practiced in our centre as well. However the most effective prevention is awareness of the operating surgeons and anesthesiologists involved.

Conclusion

Entrapment of the central venous catheter after cardiac surgical procedure is a rare but a potential complication. Any irrational measures like excessive traction should be avoided. Surgical removal is recommended.

References

1. McGee DC, Gould MK. Preventing complications of central venous catheterization. *N Engl J Med* 2003;348:1123-33.
2. Anvaripour A, Yazdanian F, Totonchi MZ, Shahryari H. Inadvertent entrapment of a central venous catheter by a purse-string suture during cardiopulmonary bypass: A Case Report. *Case Rep Anesthesiol* 2011; Article ID 760426, 4 pages, 2011.
3. Mahadeva S, Cohen A, Bellamy M. The stuck central venous catheter: beware of potential hazards. *Br J Anaesth* 2002;89:650-2.
4. Kong H, Chen S, Wen X. Suture of the right internal jugular vein catheter in a mitral valve replacement: a case report. *J Med Case Rep* 2014;8:129.
5. Kaplan M, Demirtas M, Cimen S, Kut MS, Ozay B, Kanca A, et al. Swan-Ganz catheter entrapment in open heart surgery. *J Card Surg* 2000;15:313-5.
6. Huang L, Elsharydah A, Nawabi A, Cork RC. Entrapment of pulmonary artery catheter in a suture at the inferior vena cava cannulation site. *J Clin Anesth* 2004;16:557-9.
7. Jeon Y, Ryu HG, Yoon SZ, Kim JH, Bahk JH. Transesophageal echocardiographic evaluation of ECG-guided central venous catheter placement. *Can J Anaesth* 2006;53:978-83.
8. Alsatli R. Pulmonary artery catheter entrapment in cardiac surgery. *Saudi J Anaesth* 2010;4:114-6.
9. Huang GS, Wang HJ, Chen CH, Ho ST and Wong CS .Pulmonary artery rupture after attempted removal of a pulmonary artery catheter. *Anesth Anal* 2002;95:299–301.